

Effect of AREDS2 Plus a Resveratrol-Rich Formulation on Atrophic Age-Related Macular Degeneration: a Case Report

Francis C. Lau, Ph.D.¹, Bruce P. Daggy, Ph.D.¹, Robert T. McHugh, O.D.² and Jack L. Hollins, M.D.³

¹Shaklee Research Center, Pleasanton, CA, ²McHugh Optometry, Morehead, KY, ³Hollins Ophthalmology, Lexington, KY

BACKGROUND AND OBJECTIVES

Age-related macular degeneration (AMD) is a leading cause of blindness worldwide with limited pharmaceutical and surgical treatment options. In the United States, more than 50% of all blindness is caused by AMD. AMD is characterized by damage to the macula, a region of the retina. The etiology of AMD is largely unclear but it is associated with aging and other risk factors including genetics, hypertension, cardiovascular disease, obesity, and smoking.

Nutrient-based preventive treatments for AMD have been evaluated in age-related eye disease study (AREDS) and AREDS2. AREDS2 formulation has been shown to significantly reduce the risk of developing advanced AMD. Case studies indicate that remission of AMD, though rare, does occur spontaneously. In this regard, retinal regeneration is possible. The purpose of the current study was to investigate the effects of combining AREDS2 treatment with a resveratrol/polyphenol-enriched supplement on macular structure and visual function in dry AMD patients.

CASE REPORT

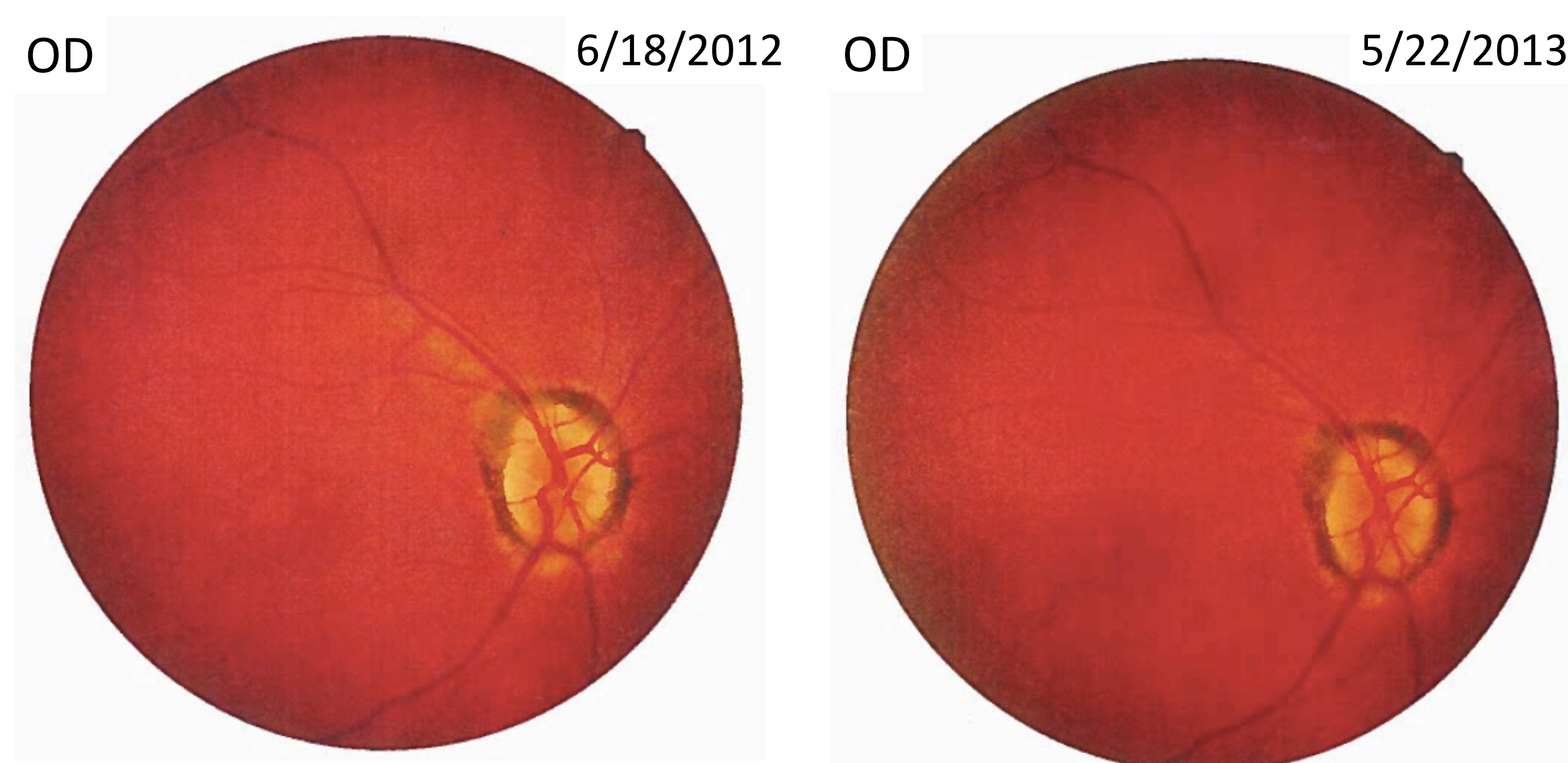
Chief complaint: Vision changes in the right eye

History of related illness: A 67 year old female in good health has a history of a damaged left eye from trauma with no central vision and dry macular degeneration with soft drusen in her right eye. The dry AMD was evident with no changes for about 3 years. She then noticed a gradual decrease in vision over a 4 month period. Her vision had decreased from 20/30 to 20/70 Snellen. A consult with two retinal specialist ophthalmologists confirmed the AMD to be dry.

Past treatment: AREDS2 formulation

Current treatment: AREDS2 plus Resveratrol/polyphenol-rich supplement (RPS)

Figure 1. Color fundus photos

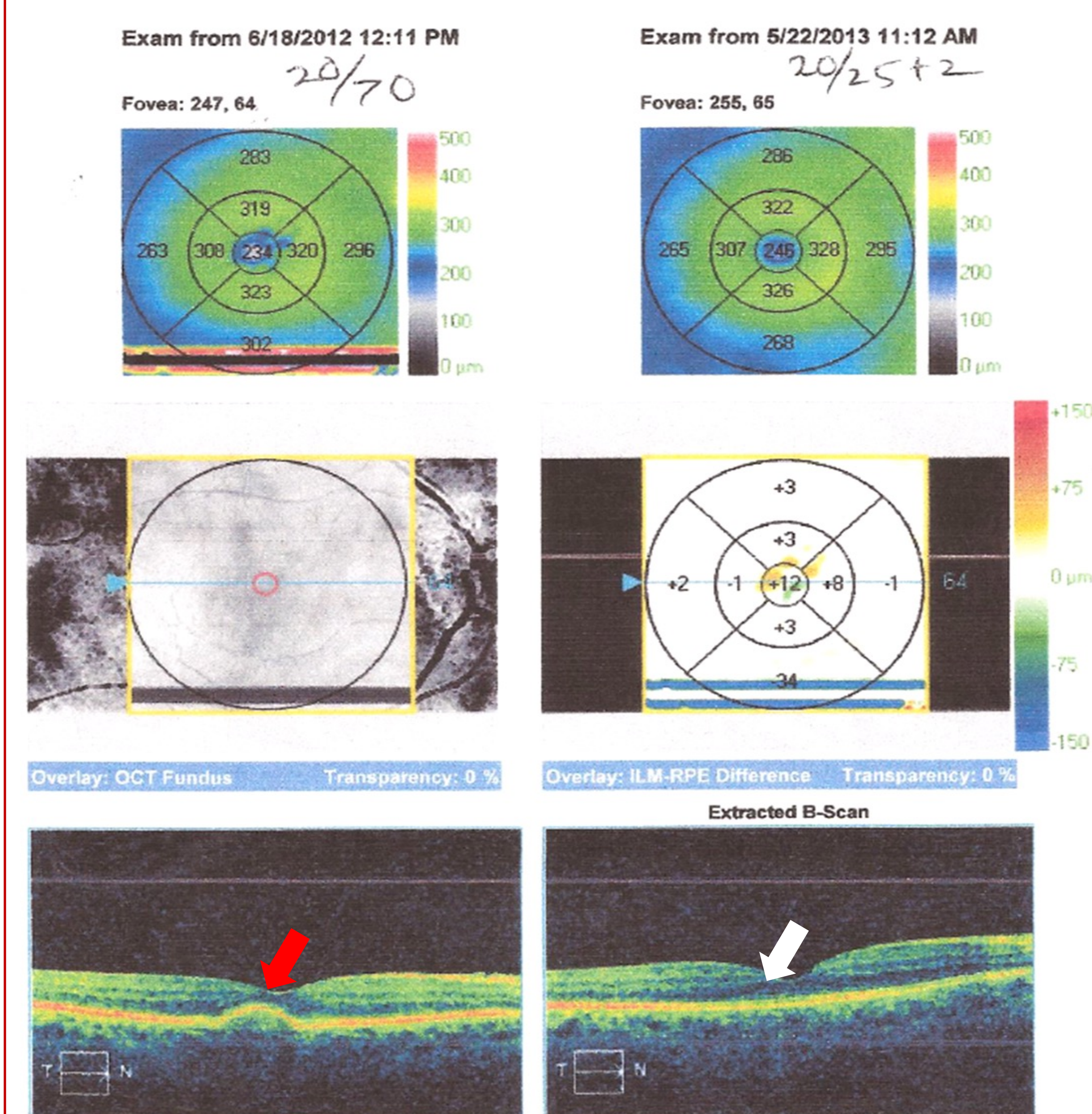


Comparison of color fundus photos after 11 months of RPS supplementation in combination with AREDS2.

RESULTS

Supplementation with AREDS2 plus RPS restored the subject's vision in her right eye from 20/70 to 20/30 after 4 months. After 11 months, the distorted retinal pigment epithelium was restored (Fig. 2) resulting in an improved vision of 5 Snellen lines to 20/25.

Figure 2. Optical coherence tomography



After taking RPS in addition to ADREDS2 formulation for 4 months, the subject's vision returned to 20/30. After about 11 months her vision improved 5 Snellen lines to 20/25. The large drusen (red arrow) distorting her vision had disappeared (white arrow).

CONCLUSIONS

Supplementation with AREDS2 plus RPS resulted in improvements in vision and macular structure. The current case report does not distinguish whether the effects of resveratrol/polyphenol preparation on retinal structure/function depend on synergistic interactions with AREDS2, or if resveratrol/polyphenols alone are responsible.

Future well-controlled clinical trials are warranted to evaluate the beneficial effects of RPS alone and in combination with AREDS2 formulation in the treatment of dry AMD.