

What are the Risks of Chiropractic Neck Adjustments?

© 2003, William J. Laretti, DC

From time to time, news items have reported on the supposed risks of chiropractic manipulation to the neck. As a practicing chiropractor who uses neck manipulation everyday in my practice, I find these reports exaggerated and alarmist.

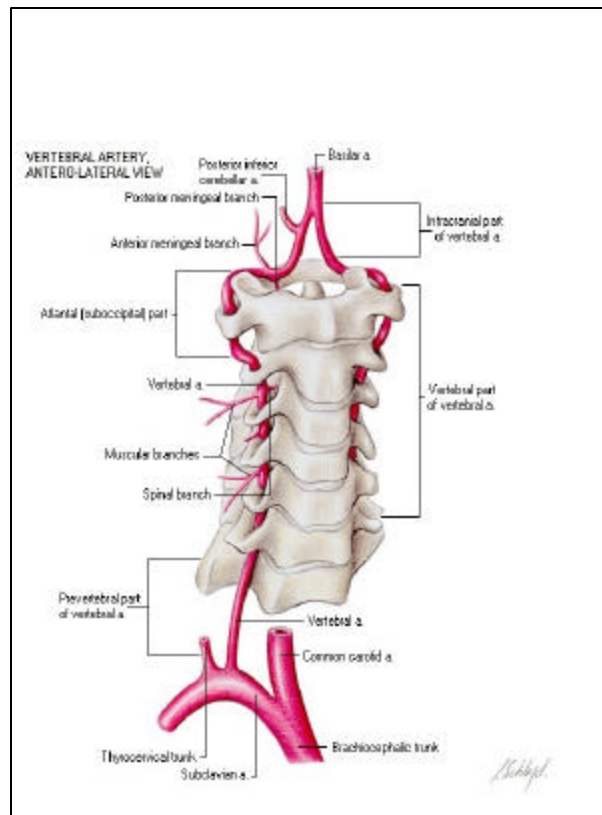
I've been in practice for over 12 years, and I've personally performed well over 15,000 neck adjustments without a single serious complication that I am aware of. I often perform neck adjustments on my friends, family and loved ones, and often receive them myself from colleagues. Based on the available scientific evidence and my past clinical experience, I'm personally convinced that neck adjustments are a very safe and very effective form of treatment. Clearly, the risks of neck manipulation are not as extreme as some of the more irresponsible reports imply.

Stroke and Neck Manipulation

Criticisms regarding the safety of chiropractic neck treatments usually focus on the remote risk of a stroke or cerebrovascular accident (CVA) occurring as a result of the treatment.

The most likely mechanism of stroke from neck movement involves injury to the vertebral artery (VA) as it goes through the sides of the upper cervical vertebrae and into the base of the skull. The part of the artery that passes through the cervical spine is called the vertebral artery. The continuation of the artery into the base of the brain is called the basilar artery. Both sections together are usually called the vertebrobasilar system.

Rotation of the neck may injure an abnormally fragile vertebral artery along its course by partially tearing the inner artery wall (the intima). This event is called a vertebral artery dissection (VAD).



The injury to the arterial wall may lead to formation of a blood clot. Part of the clot (called an embolus) can break free, travel upward into the basilar artery, and lodge in one of the smaller blood vessels branching off the basilar artery and going into the base of the brain. This can result in ischemic stroke, or a lack of blood supply to these brain tissues.

Traumatic or spontaneous dissection can also occur in the other major artery in the neck, the carotid artery, and can also lead to a stroke. However, it is highly unlikely that these injuries can be caused by neck manipulation. This is because there is no plausible mechanism where the carotid artery can be significantly injured by turning the head, since it located in the front of the neck, is much more movable, and is not constrained by passing through the cervical vertebrae, like the vertebral artery.

Cervical manipulation is not the only mechanism to initiate a vertebral artery injury. The medical literature contains numerous reports of similar arterial dissections resulting from common medical procedures such as administering anesthesia during surgery (1-2), or while extending the neck during dental procedures or taking X-rays (3). Cases of vertebrobasilar accidents have been reported which apparently occurred during normal activities such as talking on the telephone, swimming, yoga, stargazing, overhead work, sexual intercourse, and even during sleep. "Beauty Parlor Stroke," caused by extending the neck over a sink while washing the hair, is also well-documented (4-5).

Vertebral artery dissections can occur in all ages, although they are relatively more common in younger people; 70% of cases occur in persons aged 35-50 years. The female-to-male ratio is 3:1. In the US, the combined incidence of both vertebral artery dissection and its related condition carotid artery dissection is estimated to be 2.6 per 100,000 persons. Dissections of the carotid arteries are estimated to be 3-5 times more common than dissections of the vertebral arteries. Despite their rarity, cervical artery dissections are responsible for as many as 20% of the ischemic strokes in younger patients (age 30-45) (6).

The typical presentation of VAD is a younger person with a severe headache at the base of the skull and severe pain in the back of the neck following a recent, relatively minor, twist or turn of the neck. Neurologic signs suggesting a stroke (ex. dizziness, nausea, double vision, loss of feeling or weakness) eventually develop in 85% of all patients. However, a latent period as long as 3 days between the onset of neck pain and the development of obvious neurological signs is not uncommon. Delays of weeks and even years have also been reported.

The condition likely has a multifactorial etiology, involving both genetic and environmental factors.

Most cases of VAD are spontaneous in nature—their history does not involve severe blunt or penetrating trauma as a precipitating factor. However, even in cases of severe neck trauma resulting from a motor vehicle accident, a fall or a penetrating neck injury, dissections of the vertebral artery are exceedingly rare. This indicates that these arteries are normally very elastic and resilient to injury; it also suggests that it is unlikely that a normal artery would be damaged by the minor strains it would experience during a

skillfully performed neck adjustment.

Other Risk Factors for Arterial Dissection:

Possible Infectious Cause: One recent case-control study established a recent respiratory tract infection as a possible risk factor of spontaneous carotid and vertebral artery dissections, a possibility supported by the seasonal variation in this condition, with a peak occurrence in the autumn (7).

This correlation might be explained by the hypothesis that an upper respiratory infection triggers an inflammatory cascade that adds a critical amount of stress to a neck artery that is already weaker than normal due to a pre-existing connective tissue abnormality.

Other recent studies suggest that mildly increased blood levels of homocystine, an amino acid associated with other cardiovascular diseases, might also be a risk factor for arterial dissections in the neck (8). This association might be explained by the hypothesis that the elevated level of homocystine is a marker indicating generally poor cardiovascular health, and may be associated with an underlying condition of weakened blood vessel walls. A common cause of elevated homocystine levels is a deficiency of various B vitamins associated with poor diet, malabsorption syndromes, smoking and alcohol abuse.

Several inheritable connective tissue disorders are associated with an increased risk of vertebral and carotid artery dissection, including:

- ◆ **Ehlers-Danlos Syndrome (EDS) type IV**, an inheritable disorder characterized by weakened linings of the walls of blood vessels and the intestine. Type IV EDS is associated with minimal skin and joint hyperextensibility, but is associated with a notable tendency toward easy bruising.
- ◆ **Marfan's Syndrome**, a generalized disorder of connective tissue with skeletal, ocular and cardiovascular manifestations. Characteristically, the affected person is tall and thin with long extremities, and often have long, thin and hyperextensible fingers; deformities of the sternum and spinal kyphosis is common.
- ◆ **Osteogenesis Imperfecta**, a generalized inheritable disorder of the connective tissue associated with abnormal fragility of the skeleton, easy bruising, abnormal dentition and blue sclerae.

The “Epidemic” of Vertebral Artery Dissections

With the increasing availability of noninvasive imaging technologies, in particular magnetic resonance imaging (MRI), many patients who present with subtle manifestations of the condition are now being diagnosed as having a vertebral artery dissection. Although still considered a rare form of stroke, the number of diagnosed cases of vertebral artery dissection from all causes has increased notably in recent years.

The Question of Causation

Many of the cases where vertebral artery stroke appears to be correlated with a chiropractic visit may not have been caused by the actual treatment.

It is common that a vertebral artery dissection can be preceded by symptoms of headache or neck pain days— or even weeks— before the actual stroke occurs. This pain might come from the evolving injury to the arterial wall.

The “true stroke” might occur later only after the formation of a blood clot at the site of injury, which then breaks free and lodges in one of the blood vessels in the base of the brain.

Therefore, it is possible that in many of the cases where a VA dissection and stroke is temporally correlated with a chiropractic visit, the stroke may not have been caused by the treatment itself. The patient may have been seeing the chiropractor for treatment of the symptoms that were actually caused by the evolving arterial dissection.

The warning signs that may indicate a patient is in the process of experiencing a vertebral artery dissection are often subtle and difficult to recognize for even the most experienced and knowledgeable practitioner. They can easily be mistaken for more common, and less serious, causes of neck pain and headache. Currently, no simple and inexpensive screening test exists that can reliably determine if a patient’s neck symptoms are being caused by a vertebral artery dissection or a much more common cause such as muscular tightness or joint stiffness.

A recent biomechanical study (9) measured the forces transmitted to the vertebral artery during vigorous cervical spine manipulation. This study found that the forces transmitted to the artery during this procedure are less than 1/9th the force necessary to stretch or otherwise damage a normal vertebral artery. The forces measured during a neck manipulation were actually less than the forces measured during normal range-of-motion movements of the neck. Based upon recent evidence, many experts now believe that it is physically impossible for a competently performed neck adjustment to cause a vertebral artery dissection unless the artery already has a significant pre-existing weakness.

Outcomes from Vertebral Artery Dissection

Strokes of the vertebrobasilar circulation usually result in signs of brainstem injury such as severe nausea and vomiting, visual problems, or dizziness. These symptoms can vary in severity, and can become permanent.

Strokes of the posterior circulation can also result in Wallenberg’s syndrome, where there is loss of pain and temperature of the face on the same side of the injury, and loss of pain and temperature of the body on the opposite side of the injury.

Although the outcome of vertebrobasilar strokes can catastrophic, only a minority of these strokes is fatal or results in severe disability. One retrospective analysis of hospital

records followed up on 26 patients who suffered VAD from a variety of causes: 83% had a favorable outcome and there was a low recurrence rate. (10)

Appropriateness of Cervical Manipulation

The issue for any healthcare intervention is appropriateness. This involves balancing safety and effectiveness—The Risk/Benefit Ratio. Anyone who only wants to discuss risk and not potential benefit is demonstrating a bias or doesn't understand the issue.

Many scientific studies and expert reviews show that neck manipulation (or chiropractic cervical adjustment) is safe, effective and appropriate for patients with common forms of neck pain and headache.

- **Quebec Task Force Report on Whiplash Injuries (1995)** (11)
A multispecialty panel of leading researchers and clinicians from North America and Europe reviewed the scientific literature and provided treatment guidelines for whiplash-type injuries to the neck.
Joint manipulation and mobilization were recommended to improve range of motion and reduce pain, and as part of a management strategy based on early return to function and activities as opposed to rest or use of a cervical collar.
- **RAND Corporation Report (1996)** (12)
This report, based on the work of a multidisciplinary expert panel including chiropractors, neurologists, a neurosurgeon, an orthopedic surgeon and primary care physicians:
Concluded that “manipulation is probably slightly more effective than mobilization or physical therapy for some patients with sub-acute or chronic neck pain, and all three treatments are probably superior to usual medical care.” Also concluded that “Manipulation and/or mobilization may be beneficial for muscle tension headache.”
- **Duke University Evidence Report (2001)** (13)
This systematic review of the scientific evidence for treatments of headache was performed by the Duke University Evidence-Based Practice Center. It found cervical manipulation appropriate for both tension-type headache and cervicogenic headache—a sub-category of tension headache that is associated with specific neck symptoms. In addition, it noted that “cervical spinal manipulation has a very low risk of serious complications” which may be “one of its appeals over drug treatment.”

Chiropractic neck manipulation has proven specific physiological benefits. Studies have shown that cervical manipulation produces a consistent and significant increase in the active range of motion, and that this benefit remains for many weeks after the treatment is complete (14).

Risk Estimates

The best estimates of the odds of suffering a serious complication from a chiropractic neck treatment are about one incident out of every two million treatments (15-16). That means that you would expect one chiropractor out of 25 to see such an incident throughout their entire careers, if they are each in full-time practice for 40 years (17).

In other words, the great majority of practicing chiropractors will never see such an incident in their lives, despite the fact that most chiropractors perform hundreds or thousands of neck adjustments per year. These events seem to have gotten a disproportionate amount of attention in the medical literature, considering how extraordinarily infrequently they occur.

To properly assess the risks of chiropractic treatment, it must be compared against the risks of other treatments for similar conditions. For example, even the most conservative conventional treatment for neck and back pain—prescription non-steroidal anti-inflammatory drugs (NSAIDs)—may carry significantly greater risk than the drug-free chiropractic approach to these conditions (18-23).

Less conservative treatments such as neck surgery are also used for some conditions similar to those chiropractors treat with spinal adjustments. There is a three to four percent rate of complication for cervical spine surgery (24), and 4,000-10,000 deaths per million. These risk rates are thousands of times greater than the most extreme estimates of risks from spinal adjustments.

Even bed rest, a mainstay of conservative treatment for back and neck pain in the past, carries substantial risks. These risks include muscle wasting (1.0 to 1.5 percent of muscle mass lost per day); cardiopulmonary deconditioning (15 percent loss in aerobic capacity in 10 days); bone mineral loss, and the risk of thromboembolism (blood clots) (25). The social and psychological side effects of prolonged bed rest are also considerable. Current evidence suggests that more than two to four days of bed rest does more harm than good.

Moreover, “doing nothing,” i.e. not treating patients with neck and back pain, carries risks as well. These may include increased rates of disability, abuse of prescription narcotics or illegal drugs for pain relief, disruption of work and social activities, and the risk that an uncomplicated short-term pain condition will become chronic and permanent.

In summary, although all available evidence demonstrates that there is an extremely small risk of major complications from chiropractic neck treatments, this is an area of concern for the chiropractic profession. Doctors of chiropractic have contributed valuable research to the physiological, epidemiological and clinical understanding of these injuries (9, 15-17). Our profession seeks to work closely with other medical professionals on this matter, for the best interests of our patients.

TABLE 1. Estimated risks of common chiropractic treatments, common medical treatments and accidents.

Procedure or Activity	Estimated Risk	Source
Risk of death in fatal air crash, flying three hours on a U.S. commercial airline	1 in 2,000,000	(26)
Risk of death in motor vehicle accident, driving 35 miles	1 in 2,000,000	(27)
Risk of serious stroke or neurological complication resulting from a chiropractic neck adjustment	1 in 2,000,000 treatments (best estimate): Range from 1:500,000 to 1:5,000,000	(15-17)
Risk of being injured in motor vehicle accident, driving ½ mile	1 in 2,000,000	(27)
Risk of death, per year, from GI bleeding due to NSAID use for osteoarthritis and related conditions	800 in 2,000,000	(21)
Overall Mortality rate for spinal surgery	7 in 10,000	(25)
Death rate from cervical spine surgery	4-10 in 10,000	(24)
Rate of serious or life-threatening complications from spinal stenosis surgery	5 in 100	(25)
Risk of a developing a gastric ulcer visible on endoscopic examination after 1 week's treatment with naproxen (at 500mg twice daily	19 in 100 (380,000 in 2,000,000)	(19)

References

1. Fisher M: Basilar artery embolism after surgery under general anesthesia: a case report. *Neurology* 1993; 43:1856.
2. Fogelholm R, Karli P: Iatrogenic brainstem infarction. *Eur Neurol* 1975; 13:6.
3. Okawara S, Nibblelink D: Vertebral artery occlusion following hyperextension and rotation of the head. *Stroke* 1974; 5:640.
4. Chang GY, Ahn PC: Postcoital vertebral artery dissection. *Am Fam Physician* 1996; 54:2195.
5. Weintraub MI: Beauty parlor stroke syndrome: report of five cases. *J Am Med Assoc* 1993; 269(16):2085.
6. Lang E, Afilalo M. Dissection, Vertebral Artery. *E-medicine* (updated January 22, 2003). www.emedicine.com/emerg/topic832.htm
7. Grau AJ, Brandt T, Buggle F, et al: Association of cervical artery dissection with recent infection. *Arch Neurol* 1999; 56:851.
8. Mild hyperhomocyst(e)inemia: A possible risk factor for cervical artery dissection. Gallai V, Caso V, et al. *Stroke* 2002; 32:714.
9. Symons BP, Leonard T, Herzog W. Internal Forces Sustained by the Vertebral Artery During Spinal Manipulative Therapy. *J Manipulative Physiol Ther* 2002; 25:504-10.
10. Saeed AB, Shuaib A, et al. Vertebral artery dissection: warning symptoms, clinical features and prognosis in 26 patients. *Can J Neurol Sci* 2000; 27 (4):292.
11. Spitzer WO, Skovron ML, et al. Scientific Monograph of the Quebec Task Force on Whiplash-associated Disorders: Redefining Whiplash and its Management. *Spine* 1995; 20:8S.
12. Coulter ID, Hurwitz EL, et al. The Appropriateness of Manipulation and Mobilization of the Cervical Spine. Santa Monica, CA: RAND, 1996. Doc. No. MR-781-CR.

13. McCrory DC, Penzien DB, et al. Evidence Report: Behavioral and Physical Treatments for Tension-Type and Cervicogenic Headache. Des Moines, IA: Foundation for Chiropractic Education and Research, 2001. Product No. 2085.
14. Whittingham W, Nilsson N. Active Range of Motion in the Cervical Spine Increases after Spinal Manipulation. *J Manipulative Physiol Ther* 2001; 24(9):552-5.
15. Terrett AGJ: Current Concepts in Vertebrobasilar Complications following Spinal Manipulation. West Des Moines, IA: NCMIC Group, Inc., 2001
16. Klougart N, Leboeuf-Yde C, Rasmussen LR: Safety in chiropractic practice part I: The occurrence of cerebrovascular accidents after manipulation to the neck in Denmark from 1978-1988. *J Manipulative Physiol Ther* 1996; 19:371.
17. Haldeman S, Carey P, Townsend M, Papadopoulos C: Arterial dissections following cervical manipulation: the chiropractic experience. *CMAJ* 2001;165:905.
18. Dabbs V, Lauretti WJ. A risk assessment of cervical manipulation vs. NSAIDs for the treatment of neck pain. *J Manip Physiol Ther* 1995; 18(8): 530.
19. Armstrong CP, Blower AL: Nonsteroidal anti-inflammatory drugs and life threatening complications of peptic ulceration. *Gut* 1987; 28:527.
20. Babb R: Gastrointestinal complications of nonsteroidal anti-inflammatory drugs. *West Journal Med* 1992; 157:444.
21. Fries JF: Assessing and understanding patient risk. *Scan J Rheumatol* 1992; suppl. 92:21.
22. Wolfe MM, Lichtenstein DR, Singh G: Gastrointestinal toxicity of nonsteroidal anti-inflammatory drugs. *NEJM* 1999; 340:1888.
23. Gabriel SE, Jaakkimainen L, Bombardier C: Risk for serious gastrointestinal complications related to use of nonsteroidal anti-inflammatory drugs; A meta-analysis. *Ann Int Med* 1991; 115:787.
24. The cervical spine research society editorial committee: *The cervical spine* (2nd edition). New York: J.B. Lippincott Company, 1989.
25. Bigos S, Bowyer O, Braen G, et al: *Acute Low Back Problems in Adults*. Clinical Practice Guideline No. 14. Rockville, Maryland, 1994, U.S. Department of Health and Human Services, Public Health Service, Agency for Health Care Policy and Research, AHCPR Pub. Nos. 95-0642-3.
26. Based on 1997-2000 Transportation Statistics showing an average of 1.57 deaths per 1,000,000 flight hours <http://www.bts.gov/publications/nts/>
27. Based on 1.5 deaths per 100 million vehicle miles and 116 injuries per 100 million miles traveled in 2000: Traffic Safety Facts 2000. National Highway Traffic Safety Administration <http://www.nhtsa.dot.gov/>.

**The above is © 2003, William J. Lauretti, DC,
who is solely responsible for its content.**

For more information,

Call: 301-258-8877

E-mail: bill-lau@chiro.org